Journal of Health Science 6 (2018) 304-309
doi: 10.17265/2328-7136/2018.04.009

Diagnostic Utility of Indigenous Technique of Pleuroscopy in Undiagnosed Cases of Exudative Pleural Effusions

Bhavya Atul Shah[1], Mahendra Singh Raghuvanshi[1], Tapan Surana[1], Navedeep Labana[1], Mohammad Zeeshan Mansuri[1] and H. G. Varudkar[2]

1. Post Graduate Resident

2. Professor and Head, Department of Pulmonary Medicine, R.D. Gardi Medical College, Ujjain 456006, India

Abstract: Background and Aims: Since our rural institution has limited resources we always choose economical options. Recently, indigenous technique of pleuroscopy is gaining popularity due to various advantages. We developed indigenous technique of medical thoracoscopy has been developed and done by using set of patented conduits and fiberoptic bronchoscope (FOB).Therefore, we have used this technique for undiagnosed pleural effusions. Methods: An observational study was conducted in 79 undiagnosed cases of exudative pleural effusion from June 2016 to January 2017. Indigenous technique consists of use of fiber optic bronchoscope through various metallic conduits to be used in specified order for medical thoracoscopy. Procedure is done under conscious sedation and conduits are passed one after another in a specified order, through the chest stoma. The visualization of pleural cavity and various procedures were done with FOB (fiberoptic bronchoscope). Results: Out of the 79 cases, the appearance of pleura showed, inflamed/reddened pleura in 16 (20.2%) cases, thin transparent adhesions in 18 (22.7%), thin transparent loculations in 16 (20.2%) cases, thick loculations in 6 (7.6%) cases, hard pleural surface in 5 (6.3%), large nodule/masses in 6 (7.6%), small milliary seedlings or sago grain appearance in 6 (7.6%), scattered masses or nodules in 5 (6.3%) and, broncho-pleural fistula was observed in 1 (1.2%) case. Histopathological analysis showed chronic inflammation in 34.1% (27), tubercular lesions in 24.05% (19) of patients. Primary aspergillosis and mesothelioma each has 1 case, and the rest 29.11 % (23) were pleural metastasis. Thus, diagnostic yield of pleuroscopy pleural biopsy was 89.9% (71). Conclusion: Indigenous technique appears to be an efficient and relatively safe procedure with good diagnostic yield in undiagnosed pleural effusions.

Key words: Pleural effusion, pleuroscopy, thoracoscopy, indigenous technique, diagnostic utility, fiberoptic bronchoscope.

1. Introduction

Medical thoracoscopy was described for diagnostic purpose by Jacobaeus [1] in 1910 in tubercular pleural effusions. However, with efficient chemotherapy the procedure was abandoned for some time. With advances of fiberoptics, there is a renewed interest in thoracoscopy.

Use of FOB (fiberoptic bronchoscope) in the pleural space due to its inherent physical properties, is difficult to control the movements. The indigenous pleuroscopy [2] technique developed offers a solution to these problems. This technique combines the advantages of the flexibility of the fiber optic bronchoscope and the rigidity of conventional thoracoscope.

In the present study, efforts are made to evaluate the accuracy of diagnosis with the indigenous technique of pleuroscopy in patients of undiagnosed exudative pleural effusions.

2. Material and Method

This study was conducted in the Department of Pulmonary Medicine, R. D. Gardi Medical College, Ujjain, from June 2016 to September 2017. All patients with effusion were investigated with thorough clinical,

Corresponding author: Dr. H. G. Varudkar, M.D., Ph.D., professor and Head, Department of Pulmonary Medicine, research fields: pleural disease, bronchoscopy, allergy and asthma, pleuroscopy, tuberculosis.

radio-pathological, microbiological and biochemical investigations. In spite of all these investigations, those remained undiagnosed were included in the study. Other inclusion criteria were following: patient's age more than 18 years; having exudative moderate to massive pleural effusion diagnosed on the basis of Light's criteria [3]. However, absence of adequate pleural space; bleeding tendencies; patients not giving consent were excluded from study. Other contraindications for pleuroscopy included cardiac arrhythmias and intractable cough.

All the studied patients were investigated with complete blood count including bleeding time/clotting time (BT/CT), platelet count. Vascular access was achieved with intravenous cannula inserted in the upper limb opposite to the side of pleuroscopy. Patients were positioned in lateral decubitus with effusion side up. The arm on side of pleuroscopy was positioned above the patient's head and sand bag was positioned under the chest to widen the spaces which allowed better access. The procedure was conducted under local anesthesia and conscious sedation. Chest wall was draped with sterile cloth after cleaning the skin with spirit and 5% povidone iodine. The skin, subcutaneous tissue, intercostal muscle and parietal pleura were anesthetized with 10 mL 2% lignocaine. During the procedure intravenous midazolam 1 mg diluted with 1 mL of normal saline was given to achieve adequate sedation. We used only single port for visualizing and taking pleural biopsy. The site of incision was chosen where diagnostic needle aspiration yielded free fluid. A 1 cm to 1.5 cm long skin incision parallel to the line of intercostal space was made using sterile surgical blade. A blunt dissection of subcutaneous tissue and the intercostal muscles, parietal pleura with artery forcep was done and after the puncture of parietal pleura a finger was passed in pleural cavity to assess adhesions.

Conduits which were used in further procedure are (Fig. 1):

(1) SBC (simple basic conduit): This device is used to drain chest contents faster without soiling the linen.

(2) SSC (simple short curved conduit): This conduit without window is used for shorter radius study of parietal pleura. It can also guide catheter insertion.

(3) PPCi (parietal pleuroscopy conduit–introducer): This conduit without any window is used for large radius parietal pleural exploration around stoma. This is a multipurpose conduit used in breakage of adhesions, opening of loculi and guiding chest tube in desired direction.

(4) PPCr (parietal pleuroscopy conduit–retractor): This instrument has spatula like patient end to be used to retract the lung to visualize better. This also protects our fibre optic bronchoscope from heat of cautery.

(5) VPC (visceral pleuroscopy conduit): This variety has conical patient end with facility of general inspection of visceral pleural surface.

The SBC was inserted in the stoma to aspirate maximum fluid. After assessing the pleural cavity with finger, the SBC was replaced with SSC, and then FOB was passed through it (Fig. 2). The schematic inspection of short radius parietal pleura was done and, then as described above the conduits were used in a serial manner one after another to see all parietal, visceral, costal and diaphragmatic surface. The biopsy of

Fig. 1 Conduit set for indigenous technique of pleuroscopy.

Fig. 2 Entrance of Fiberoptic bronchoscope through the conduit.

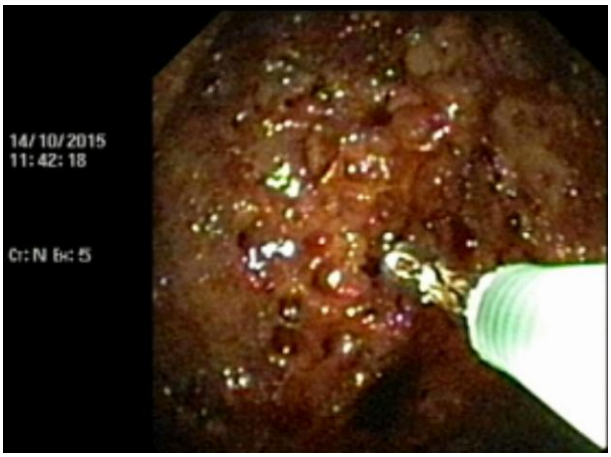

Fig. 3 Pleural Biopsy under direct vision.

abnormal area was obtained with usual biopsy forceps. Pleural bite was taken under vision with shearing movement of forceps (Fig. 3) Adhesions were gently broken using indigenous pleuroscopy conduits (SCC, PPCi, PPCr) or biopsy forceps.

After the procedure completed, bronchoscope and the conduits were removed and suitable chest tube was inserted. Chest drain was connected to water-seal drainage bag. Post-operative management was done in ward as usual. Once the lung had expanded and drain output had decreased to less than 50 mL per 24 hours, chest drain was removed and chest X-ray was done.

3. Results

During the study period, 248 cases of pleural effusions were investigated and 84 (33.8%) patients remained undiagnosed. Five patients not fitting the criteria were excluded. Thus in our study we included remaining 79 (31.5%) of undiagnosed exudative pleural effusions.

Out of the study group, 52 (65.8%) were males and 27 (34.2%) were females. 80% of patients had symptoms of less than 2 months (Table 1). 70 % of cases had moderate pleural effusion while 30 % cases had massive effusions (Table 2). Types of pleural fluid majority were straw colored (39.2%) (Table 3). 43 % of the cases had no isolation of any bacterial, and tubercular (24%), staphylocoocus (14%) and streptococcus (10%) were the common organism (Table 4). Out of the 79 cases, the appearance of pleura (Table 5) showed, inflamed/ reddened pleura in 16 (20.2%) cases, thin transparent adhesions in 18 (22.7%), thin transparent loculations in 16 (20.2%) cases, thick loculations in 6 (7.6%) cases, hard pleural surface in 5 (6.3%), large nodule/masses in 6 (7.6%), small milliary seedlings or sago grain appearance in 6 (7.6%), scattered masses or nodules in 5 (6.3%) and, broncho-pleural fistula was observed in 1 (1.2%) cases. Histopathological analysis (Table 6) showed chronic inflammation in 34.1% (27), Tubercular lesions in 24.05% (19) of patients. Primary Aspergillosis and mesothelioma each 1 cases, and the rest 29.11 % (23) were pleural metastasis. Thus, diagnostic yield of pleuroscopy pleural biopsy was 89.9% (71).

Table 1 Duration of symptoms.

Sr. No.	Duration of symptoms	No. of patients		Total number (%)
		Male	Female	
1.	Less than 15 days	19	9	28 (35.4%)
2.	16 to 2 months	22	13	35 (44.3%)
3.	More than 2 months	11	5	16 (20.2%)
	Total	52 (65.8%)	27 (34.2%)	79 (100%)

80% of patients had symptoms of less than 2 months.

Table 2 Quantity of fluids.

Sr. No.	Quantity of fluid	No. of patients		Total number (%)
		Male	Female	
1.	Minimal	0	0	0
2.	Moderate	36	19	55 (69.6%)
3.	Massive	16	8	24 (30.4%)
	Total	52	27	79 (100%)

70% of cases had moderate pleural effusion while 30% cases had massive effusions.

Table 3 Type of fluid.

Sr. No.	Type of fluid	No. of patients		Total number (%)
		Male	Female	
1.	Serous	8	5	13 (16.5%)
2.	Pus	14	6	20 (25.3%)
3.	Blood mixed	9	6	15 (19%)
4.	Straw colored	21	10	31 (39.2%)
	Total	52	27	79 (100%)

Types of pleural fluid majority were straw colored (39.2%).

Table 4 Isolation of organism.

Sr. No.	Organism isolated in culture	No. of patients		Total number (%)
		Male	Female	
1.	Staphylococcus	8	5	11 (16.6%)
2.	Streptococcus	5	3	8 (10%)
3.	Pseudomonas	2	0	2 (2.6%)
4.	Tubercular	12	7	19 (24%)
5.	Aspergillus	1	0	1 (1.2%)
6.	Klebsiella	1	1	2 (2.6%)
7.	No growth	23	11	34 (43%)
	Total	52	27	79 (100%)

43% of the cases had no isolation of any bacterial, and tubercular (24%), staphylocoocus (14%) and streptococcus (10%) were the common organism.

Table 5 Pleural appearance on pleuroscopy with indigenous technique.

Sr. No.	Pleural finding	No. of cases	Percentage %
1.	Red pleura	16	20.2
2.	Thin transparent adhesions	18	22.7
3.	Thin/transparent loculations	16	20.2
4.	Thick loculation	6	7.6
5.	Hard pleural surface	5	6.3
6.	Large nodules/Masses	11	13.9
7.	Small milliary seedlings/Sago grain appearance	6	7.6
8.	Broncho-pleural fistula	1	1.2
	Total	79	100

Table 6 Histopathological diagnosis obtained with indigenous technique of pleuroscopy.

Sr. No.	Histopathological results	No. of cases	Percentage
1.	Chronic inflammation	27	34.1%
2.	Tubercular lesions	19	24.05%
3.	Pleural metastasis	23	29.11%
4.	Primary Aspergillosis	1	1.2%
5.	Mesothelioma	1	1.2%
6.	Non-specific/fibrotic changes	8	10.1%
	Total	79	100%

4. Discussion

We have presented the data of 79 patients who underwent pleuroscopy with indigenous technique. We included patients for pleuroscopy in whom initial diagnostic work-up with pleural fluid analysis and three pleural fluid cytology did not give any diagnosis.

In our study, we have 52 (65.8%) males and 27 (34.2%) females, with majority of patients having symptoms less than 2-month period. Some of our patients might be affected by previous treatment.

For indigenous technique, it is mandatory that there should be some free fluid for entry of the conduits and further intervention can be done under direct vision. Therefore, we have not included patients with minimal effusions. However complicated effusion was not a contradiction with this technique because the conduits especially PPCr and PPCi are useful for intra thoracic maneuvers.

Table 3 reveals that the straw colored fluid was predominant finding in undiagnosed cases of exudative pleural effusions.

We got variety of organisms isolated in the culture of pleural fluid in which *Mycobacterium tuberculosis* (24%) was most common organism isolated and rest were *Staphylococcus*, *Streptococcous*, *Pseudomopnas*, *Klebsiella* and *Aspergillus*. Although maximum samples 43%, showed no growth, the reasons for no growth are non-pyogenic etiology, or previous antibiotic treatment.

We have got diversified range of pleural appearance with indigenous technique of Pleuroscopy and every case was different from previous one. We tried to classify pleural appearance and found in different categories in which Pleuroscopy appearance of pleura showed, inflamed/reddened pleura in 16 (20.2%) cases, thin transparent adhesions in 18 (22.7%), thin transparent loculations in 16 (20.2%) cases, thick loculations in 6 (7.6%) cases, hard pleural surface in 5 (6.3%), large nodule/masses in 6 (7.6%), small milliary seedlings or sago grain appearance in 6 (7.6%), scattered masses or nodules in 5 (6.3%), and broncho-pleural fistula was observed in 1 (1.2%) case. Adhesiolysis and opening of loculations were done which optimized the success of procedure with proper drainage of pleural fluid and faster re-expansion of the affected lung.

The yield of thoracoscopic pleural biopsy was 89.9% (71/79). Similar experience with medical thoracoscopy has been described from other centers. Kendall et al. [4] reported yield of thoracoscopic pleural biopsy to be 83% in their study which included 48 patients. Tscheikuna et al. [5] described their experience from Thailand (n = 86) and thoracoscopy was diagnostic in 95% of 34 patients. Although Ng et al. [6] could achieve diagnosis with thoracoscopic pleural biopsy in only 45.5% (10/22) patients, in a majority of patients in our study, Pleuroscopy guided pleural biopsy yielded diagnosis in undiagnosed exudative pleural effusion revealed the results as chronic inflammation followed by pleural metastasis. Twenty-three (23) cases were diagnosed as pleural metastasis, 1 case of mesothelioma and 1 case of primary aspergillosis.

Result obtained with indigenous technique after biopsy was 91% comparable with most other studies

like, Munavvar et al. [7], Wang et al. [8], Blanc et al. [9], Law et al. [10], Tscheikuna [5], Diacon et al. [11], and McLean et al. [12]. Indigenous pleuroscopy showed convincing results in diagnostic and therapeutic spectrum of interventional pleuroscopy.

A variety of complications associated with thoracoscopy have been described in the literatures [5, 9-13] such as subcutaneous emphysema (0.6%-4.9%), air leak (0.5%-8.1%), empyema (0.5%-2.7%), haemorrhage (0.3%-0.4 %), shock (0.2%), chest wall seeding by malignancy (0.5%-4.0%). We had no such complication with this indigenous technique of Pleuroscopy although some patients presented with complain of residual pain after removal of inter-coastal drain which got relived in subsequent follow-up visits with analgesics and physiotherapy.

5. Conclusion

We have achieved diagnosis in hitherto undiagnosed case of pleural effusion in a safe and effective way with our indigenous technique. The complication rates, the cost of the equipment and the technique were found to be acceptable.

References

[1] Jacobeus, H. C. 1923. "The Cauterization of Adhesions in Artificial Pneumothorax Treatment of Pulmonary Tuberculosis under Thorascopic Control." *Proc R Soc Med.* 16: 45-62.

[2] Varudkar, H. G. 2016. "Utility of Indigenous Pleuroscopy Conduits." *Thoracic Endoscopy* 1: 49-57.

[3] Light, R. W., MacGregor, M. I., Luchsinger, P. C., and Ball, W. C. J. 1972. "Pleural Effusions: The Diagnostic Separation of Transudates and Exudates." *Ann Intern Med.* 77: 507-13.

[4] Kendall, S. W., Bryan, A. J., Large, S. R., and Wells, F. C. 1992. "Pleural Effusions: Is Thoracoscopy a Reliable Investigation? A Retrospective Review." *Respir Med* 86: 437-40.

[5] Tscheikuna, J., Silairatana, S., Sangkeaw, S., and Nana, A. 2009. "Outcome of Medical Thoracoscopy." *J Med Assoc Thai* 92: S19-23.

[6] Ng, T. H., How, S. H., Kuan, Y. C., Hasmah, H., Norra, H., and Fauzi, A. R. 2008. "Medical Thoracoscopy: Pahang Experience." *Med J Malaysia* 63: 298-301.

[7] Munavvar, M., Khan, M. A., Edwards, J., Waqaruddin, Z., and Mills, J. 2007. "The Autoclavable Semirigid Thoracoscope: The Way Forward in Pleural Disease." *Eur. Respir. J.* 29: 571-4.

[8] Wang, Z., Tong, Z. H., Li, H. J., Zhao, T. T., Li, X. Y., Xu, L. L., et al. 2008. "Semi-Rigid Thoracoscopy for Undiagnosed Pleural Effusion: A Comparative Study." *Chin Med J.* 121: 1384-9.

[9] Blanc, F. X., Atassi, K. , Bignon, J., and Housset, B. 2002. "Diagnostic Value of Medical Thoracoscopy in Pleural Disease: A 6-Year Retrospective Study." *Chest* 121: 1677-83.

[10] Law, W. L., Chan, J. W., Lee, S., Ng, C. K., Lo, C. K., Ng, W. K., et al. 2008. "Pleuroscopy: Our Initial Experience in Hong Kong." *Hong Kong Med J*. 14: 178-84.

[11] Diacon, A. H., van de Wal, B. W., Wyser, C., Smedema, J. P., Bezuidenhout, J., Bolliger, C. T., et al. 2003. "Diagnostic Tools in Tuberculous Pleurisy: A Direct Comparative Study." *Eur. Respir J.* 22: 589-91.

[12] McLean, A. N., Bicknell, S. R., McAlpine, L. G., and Peacock, A. J. 1998. "Investigation of Pleural Effusion: An Evaluation of the New Olympus LTF Semiflexible Thoracofiberscope and Comparison with Abram's Needle Biopsy." *Chest* 114: 150-3.

[13] Casal, R. F., Eapen, G. A., Morice, R. C., and Jimenez, C. A. 2009. "Medical Thoracoscopy." *CurrOpinPulm Med.* 15: 313-20.