

Long-Term Evaluation of Retinal Artery Occlusion Patients Who Applied Hyperbaric Oxygen Treatment

Savas Ilbasmis¹ and Erdinc Ercan²

1. Turkish Aeromedical Research and Training Center (USAEM), Eskisehir 26010, Turkey

2. The Department of Aerospace Medicine, University of Health Sciences, Eskisehir 26010, Turkey

Abstract: Introduction: Hyperbaric oxygen treatment (HBOT) is one of the treatment modalities for retinal artery occlusion (RAO). HBOT may be beneficial if initiated within 2-12 hours of onset of symptoms. The objective of this study was to evaluate the usefulness of HBOT on the patients who had applied to our center for HBOT with an RAO diagnose. Methods: Sixteen patients were included in this study for a three-year period those were applied HBOT with RAO diagnosis. HBOT sessions of these patients had been started as quick as possible soon after they have arrived. Also, all patients had been started medication by ophthalmologists who sent them. To evaluate the outcome of the treatment the patients were called with telephone and ophthalmology clinic control examinations were obtained. Patients were asked survey questions about their visual ameliorations before and after HBOT. Results: Mean initiation duration of patients to get HBOT was about 28 hours. Only one patient has initiated treatment after 13 days from the event and no visual improvement was recorded. Within this patient, no visual amelioration was recorded for two more patients. Among the other 13 patients, three had 80% and more, three had 50-79% and seven had below 50% visual amelioration. Eleven of 13 patients had peripheral visual field amelioration. Discussion: With the medical treatment, an immediate intervention of HBOT was considered a useful treatment modality for RAO. The visual improvement of the visual fields was considered especially in the peripheral vision rather than central vision.

Key words: Retinal artery occlusion, hyperbaric oxygen therapy, visual fields, sudden vision loss.

1. Introduction

The classic presentation of retinal artery occlusion (RAO) is sudden painless loss of vision in one or less commonly both eyes. No light perception level of vision loss means occlusion at the ophthalmic artery and there would be no circulation for retinal or the choroidal circulation [1]. On ophthalmoscopic examination, patients with RAO will display a whitish, pale appearance of the maculae due to the opaque and edematous nerve fiber and ganglion cell layers (Fig. 1). A cherry red spot is often present in the fovea. Natural spontaneous re-canalization eventually takes place after RAO [2]. In few cases this reperfusion leads to an improvement of vision because the retinal tissue has been irreversibly damaged during ischemia [3].

The retina has the highest rate of oxygen consumption in the body at 13 mL/100g/min and so is very sensitive to ischemia [4]. Experimental data have shown that a total occlusion of the central retinal artery causes irreversible damage to the inner retina if occlusion time exceeds 100 minutes [5]. The leading cause of RAO is emboli deriving from arteriosclerotic plaques in the aorta or from the carotids. Further sources of emboli are calcified heart valves, thrombi originating from areas of restricted heart movements or in patients with atrial arrhythmia. Because of late application to physician and character of retina, treatment options in RAO are limited. Massage of the eyeball is one of the primary interventions. In order to reduce perfusion resistance paracentesis of the anterior chamber or administration of anti-glaucoma medication may lower the intraocular pressure [6].

Several reports exist describing a positive effect of hyperbaric oxygen treatment (HBOT) on RAO. In

Corresponding author: Savas Ilbasmis, M.D., Ph.D., aerospace medicine specialist, physiologist, research fields: aerospace medicine, HBOT and altitude physiology.

2004, European Committee for Hyperbaric Medicine accepted RAO as an optional indication of HBOT with type 3 recommendation and proof level C [7]. The objective of HBOT is to maintain an oxygen supply to the retina through the choroidal vasculature. The bradytrophic vitreous can help by serving as an oxygen deposit and under HBO regional release of tissue plasminogen activator can help to accelerate reperfusion.

RAO is an emergency and HBOT should initiate as soon as possible with other treatments to get better results. Prognosis of RAO depends on the degree of occlusion and time of delay for HBOT. HBOT may be beneficial if initiated within 2-12 hours of onset of symptoms. The objective of this study was to evaluate the usefulness of HBOT for the patients who were referred our center for HBOT with an RAO diagnosis.

2. Method

The 16 patients (age range 23-83) received emergency HBOT in our center with RAO diagnosis in a 3 years' period of 2010-2013. Emergency HBOT

session was initiated as quickly as possible for these patients. Delay time for the patients determined as the time duration between the time of incident and first HBOT session. Also, all patients have received medical treatment by an ophthalmologist who had diagnosed them as RAO and transferred them to HBOT. After the HBOT sessions, same ophthalmologists performed evaluation and follow-up of the patients.

The HBOT device used for treatments was HTC 4/2/6 model Hyperbaric Chamber that has 5 patients and 1 observer totally 6-persons capacity (Fig. 2). The HBOT sessions consisted of total 120 minutes duration 45 feet depth and 240 kPa (2.4 ATA) pressure conditions. The patients breathed 100% oxygen for 3 phases of 25 minutes and breathed cabin air for 5 minutes intervals.

About 3 months after HBOT sessions, we have interviewed the patients about the outcome of the HBOT sessions by asking about their visual improvement subjectively and follow-up examination results by phone. The questions that we have asked the patients for this purpose have shown in Table 1.

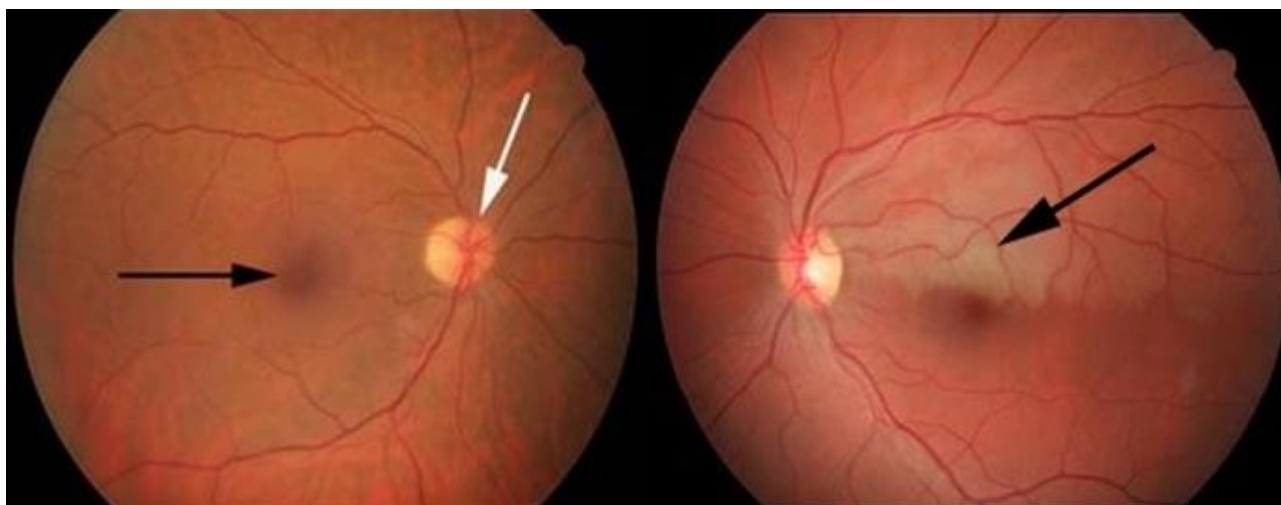


Fig. 1 Ophthalmoscopy view of normal retina (left picture). Black arrow points macula, white arrow points optical disc. The right picture shows an RAO. The area where occluded artery fed is pale comparing to other parts (black arrow).



Fig. 2 HBOT device in our center that has maximum 5 patients and 1 observer capacity.

Table 1 The survey questions after HBOT sessions.

How would you consider your vision before you started HBOT sessions? (0-10)
How would you consider which field of view remained good before the sessions?
At follow-up visits what percent visual amelioration you were told by the ophthalmologist?
How would you consider your vision after HBOT sessions? (0-10)
How would you consider which field of view turned good after the sessions?

3. Results

Mean delay time for emergency HBOT session was 28 hours (1.17 days) after the incident. Only one patient arrived for HBOT session after 13 days from the incident and no visual improvement was recorded for this patient after 8 sessions. Within this patient, no visual improvement was recorded for 2 more patients,

one of them had under 24 hours delay time. Among the other 13 patients, 3 of them had 80% and more, 3 had 50-79% and 7 had below 50% visual improvement. Eleven of 13 patients had all or peripheral visual field improvement. Mean visual improvement percent of 9 patients which had 0-24 hours delay time was 37.78%. Mean visual improvement percent of 7 patients who had delay time over 24 hours was 33.57% (Table 2).

Table 2 Individual presentation of patients followed with the RAO diagnoses.

Patient	Gender	Age	Eye	Delay*	Sessions	Q-1	Q-2	Q-3	Q-4	Q-5
1	F	23	R	0 (6 hrs)	20	0	0	20%	3	Central
2	M	35	L	2	10	1	Central	60%	6	All fields
3	F	32	R	0 (15 hrs)	10	0	0	0%	0	0
4	M	63	L	1 (28 hrs)	16	0	0	30%	3	Peripheral
5	F	47	R	13	8	1	0	0%	1	0
6	M	83	R	0 (17 hrs)	5	0	0	15%	2	Peripheral
7	M	26	R	0 (3 hrs)	3	1	All fields	95%	10	All fields
8	M	53	R	0 (9 hrs)	2	0	0	80%	9	All fields
9	F	24	L	2	5	4	Lower half	60%	9	Peripheral
10	M	69	R	1 (30 hrs)	6	0	0	20%	2	Peripheral
11	M	42	R	1 (25 hrs)	10	0	0	50%	6	Upper half
12	M	65	R	4	7	1	Peripheral	15%	2	Peripheral
13	M	52	R	5	1	2	Central	20%	4	Central
14	F	66	L	3	15	4	Upper half	80%	9	Lower half
15	M	60	R	1 (27 hrs)	12	1	Peripheral	30%	4	Central
16	M	44	L	7	4	0	0	0%	0	0

*Delay: Days or hours (hrs) of delay between the incident and first HBO session.

4. Discussion

Although number of subjects was not sufficient to make a statistical analysis, there were quite prudent percentage of subjects that had visual improvement. 81.25% of patients in these patients had little if any benefit from emergency HBOT. In addition, mean visual improvement percent of early treated (0 to 24 hours of delay) subjects with HBOT was higher than mean visual improvement percent of late treated (over 24 hours of delay) subjects. When we looked at the visual improvement fields, there were more improvements in the environmental vision areas than in the center.

A sufficient oxygenation of the retina can be achieved by HBO therapy in RAOs. However, the glucose and nutrient transport provided by retinal artery circulation is crucial for retinal ganglion cell survival. If retinal artery re-canalization does not occur in time, the neuroretinal cells die despite sufficient oxygenation. It can be discussed if a neuroprotective medication like glutamate antagonists should be given along with HBO to reduce this risk [8]. In a study, beneficial effect of HBOT compared

with a control group was described by Aisenbrey and coworkers [9]. In that study patients were treated with 3 times 30 minutes duration at 240 kPa which was applied 3 times in first day, twice daily on days 2 and 3 and once daily for at least another 4 days. The authors reporting the treatment of RAO with HBOT suggested that HBOT can be used as an emergency measure until a more radical treatment, such as surgical correction of the underlying cause, can be carried out [10].

The assessment method of visual improvement can be considered subjective since it was gathered from patients verbally. The number of subjects was very small, so detailed statistical analysis could not be done. Another limitation was that each of the patients received a different number of HBO sessions.

In this study with the medical treatment, immediate intervention of HBOT was considered a useful treatment modality for RAO. The visual improvements were especially in the peripheral visions rather than central visions. Although experimental data have shown that, a total occlusion of the central retinal artery causes irreversible damage to the inner retina if occlusion time exceeds 100

Long-Term Evaluation of Retinal Artery Occlusion Patients Who Applied Hyperbaric Oxygen Treatment

minutes, the patients who have delay times more than 24 hours should be assessed for HBOT besides medical RAO treatments. Ophthalmologists should direct patients with RAO as quickly as possible to HBOT. While continuing medical treatment, HBOT session should be arranged.

References

- [1] Regillo, D., Chang, T., and Johnson, M. 2007. "Retina and Vitreous: American Academy of Ophthalmology Basic and Clinical Science Course-Section 12." San Francisco: American Academy of Ophthalmology.
- [2] Duker, J. S., and Brown, G. C. 1988. "Recovery Following Acute Obstruction of the Retinal and Choroidal Circulations: A Case History." *Retina* 8 (4): 257-60.
- [3] David, N. J., Norton, E. W., Gass, J. D., and Beauchamp, J. 1967. "Fluorescein Angiography in Central Retinal Artery Occlusion." *Archives of Ophthalmology* 77 (5): 619-29.
- [4] Hertzog, L., Meyer, G., Carson, S., Strauss, M., and Hart, G. 1992. "Central Retinal Artery Occlusion Treated With Hyperbaric Oxygen." *Journal of Hyperbaric Medicine* 7 (1): 33-42.
- [5] Hayreh, S., and Weingeist, T. 1980. "Experimental Occlusion of the Central Artery of the Retina. I. Ophthalmoscopic and Fluorescein Fundus Angiographic Studies." *British Journal of Ophthalmology* 64 (12): 896-912.
- [6] Rossmann, H. 1980. "Treatment of Retinal Arterial Occlusion." *Ophthalmologica*. 180 (2): 68-74.
- [7] Mathieu, D. 2005. "7th European Consensus Conference on Hyperbaric Medicine." Lille, 3rd-4th December 2004. *Europ J Underwater Hyperbaric Med.* 6 (2):29-38.
- [8] Mathieu, D. 2006. *Handbook on Hyperbaric Medicine*. Netherlands: Springer.
- [9] Aisenbrey, S., Krott, R., Heller, R., Krauss, D., Rössler, G., and Heimann, K. 2000. "Hyperbaric Oxygen Therapy in Retinal Artery Occlusion." *Ophthalmologie*. 97 (7): 461-7.
- [10] Jain, K. K., and Baydin, S. 1996. *Textbook of Hyperbaric Medicine*. Switzerland: Springer International Publishing.