

Massive Pericardial Effusion as the First Manifestation of Hypothyroidism in a Male Patient

Livia Maria Carvalho Costa¹, Flávia Lunardelli Negreiros de Carvalho² and Wagner Leão Leite Tostes³

1. *General Medicine, Hospital Geral de Roraima (HGR), Boa Vista 69305455, Brazil*

2. *Residency Training Program in Anesthesiology, Universidade Federal de Roraima (UFRR), Boa Vista 693100000, Brazil*

3. *Department of Cardiology, Hospital Geral de Roraima (HGR), Boa Vista 69305455, Brazil*

Abstract: This article intends to report a rare case of massive pericardial effusion as the first manifestation of hypothyroidism. A 45-year-old male patient, accompanied by a cardiology department, suddenly started to present signs of dyspnea and tiredness. He was submitted to an echocardiogram and diagnosed with dilated cardiomyopathy associated with a moderate pericardial effusion and low ejection of fraction. The laboratory tests showed elevated TSH levels (13.20 mIU/L), what leads to the hypothyroidism diagnose and enable to start the treatment with levothyroxine. The patient has not followed correctly the treatment, reason why he has not showed any improves. He was admitted in the hospital to cardiology monitoring and the chest radiography confirmed an intense pericardial effusion. Then, the patient was submitted to the pericardiocentesis procedure, which was capable of remove the pericardial fluid for laboratory analysis and fragment of the pericardial sac for neoplastic cell research. After the hospital discharge, he was maintained in outpatient follow-up, when showed an important improvement in the clinical state.

Key words: Pericardial effusion, dilated cardiomyopathy, hypothyroidism, thyroxine, pericardiocentesis.

1. Introduction

Hypothyroidism is a clinical syndrome occasioned by reduced production of thyroid hormone [1, 2]. Its action in the organism tissues is damaged, resulting in generalized slowdown of the metabolism [3]. The hypothyroidism can be classified as primary (thyroid collapse), secondary (hypophysis collapse—TSH deficiency) or tertiary (hypothalamic deficiency of TRH). Primary hypothyroidism corresponds to approximately 99% of cases, less than 1% of them drives from TSH deficiency or other causes [4]. The incidence of this disturb is high on women and seniors, even as in some racial and ethnic groups [5].

Hypothyroidism can affect all systems and organs and its manifestations are connected to the level of hormone deficiency. The myxedema, formerly used as synonym of hypothyroidism, refers to deposition of

mucopolysaccharides in dermis, which results in edema without cacifo's sign, much more common in patients with severe hypothyroidism [4].

It has a wide symptomatology, including fatigue, somnolence, constipation, weight gain, among others. In more rare cases, the deficiency of thyroid hormone can even lead to cardiac damage, which the most known manifestation is pericardial effusion [6]. Formerly, its incidence was more elevated, it could reach even 80% [6, 7]. However, nowadays the diagnosis is usually precocious, becoming less frequent (3-5%) [8]. In the rare cases which pericardial effusion occurs, it is commonly asymptomatic, because it's insidious settlement and, often, the effusion is not significant enough to distend the pericardial sac and cause the symptoms [6, 9]. Thus, the occurrence of a massive effusion is even more unpredictable, especially as early manifestation of hypothyroidism.

2. Case Report

This is about a 45-year-old, male, obese (BMI = 43.4

Corresponding author: Larsen, P. R., M.D., FACP, FRCP, professor of medicine, research fields: endocrinology, diabetes and hypertension.

kg/m²), hypertensive and cardiopath (congestive heart failure and dilated cardiomyopathy) patient, with previous history of ischemic stroke with a cardiac etiology (atrial fibrillation). He went to a routine consultation with the cardiologist in January 2015 presenting results of an echocardiogram of 09/24/14 with diagnosis of dilated cardiomyopathy, which is associated with 37% of ejection fraction and moderate pericardial effusion. The echocardiogram was repeated on 01/24/15, it demonstrated important degeneration of the pericardial effusion condition. He was submitted to routine tests, which showed TSH of 13.20 mUI/L, and which can diagnose the man with hypothyroidism. He initiated the treatment with levothyroxine 50 mcg/day and received a referral to the thoracic surgery service and endocrinology.

The patient has returned, in December 2015, to the cardiology outpatient appointment although hasn't been following correctly the levothyroxine treatment, evolving with fatigue and dyspnea to small efforts (Forrester II and NYHA Functional Classification III). After the new echocardiogram on 01/06/16, it revealed an ejection fraction of 22%, along with severe global systolic dysfunction of left ventricle, for 45 mmHg systolic pressure in pulmonary artery and voluminous pericardial effusion with compromised diastolic

expansibility of right atrium.

He was given a referral to HGR (Hospital Geral de Roraima) on 01/20/16 to group monitoring by cardiology and endocrinology services, when the treatment with levothyroxine was reinitiated.

After hospitalization, routine laboratory tests were made (Table 1) and the chest radiography (Fig. 1) evidenced cardiac area increased and a cardiothoracic ratio of 77%. The electrocardiogram showed sinus rhythm, heart rate of 80 beats per minute, irregular rhythm, with right bundle branch block.

Chest and abdomen computed tomography (Fig. 2) took on 01/23/16 had the following results: accentuated pericardial effusion, increased cardiothoracic ratio, increased pulmonary arteries caliber (including the trunk), lungs presenting ground glass opacification and pulmonary parenchymal bands in the bases, in the abdomen just mild ascites is a highlight.

It stands out that the patient did not present classical signs of cardiac tamponade: arterial hypotension, jugular vein distention and muffled heart sounds, even though the dyspneic condition and the important pericardial effusion.

He was approached by the team of thoracic surgery on 02/23/16 for a diagnostic pericardiocentesis, with the removal of 2.200 mL liquid, which was submitted

Table 1 Results of laboratory tests performed in the hospital admission.

Laboratory tests	Results	Reference values	Laboratory tests	Results	Reference values
Complete blood count with red blood cells	5.02 × 10 ⁶ /μL	4.0-5.2 × 10 ⁶ /μL	Total bilirubin	0.70 mg/dL	0.4-1.4 mg/dL
Hematocrit	42.6%	35-46%	Direct bilirubin	0.29 mg/dL	0.0-0.4 mg/dL
Hemoglobin	13.1 g/dL	12-16 g/dL	Indirect bilirubin	0.4 mg/dL	0.4-1.0 mg/dL
White blood cells	5.000 μL	4.000-10.000 μL	LDH	459 U/L	200-480 U/L
Platelets	110 × 10 ³ /mm ³	150-450 × 10 ³ /mm ³	Uric acid	6.9 mg/dL	2.5-7.0 mg/dL
Fasting blood glucose test	99 mg/dL	60-99 mg/dL	TSH	13.20 mUI/mL	0.34-5.6 mUI/mL
Triglycerides	92 mg/dL	< 150 mg/dL	Free T4	1.15 ng/dL	0.54-1.24 ng/dL
Total cholesterol	120 mg/dL	< 200 mg/dL	Potassium	4.1 mEq/L	3.5-5.1 mEq/L
HDL cholesterol	30 mg/dL	> 60 mg/dL	Sodium	136 mEq/L	136-145 mEq/L
LDL cholesterol	72 mg/dL	< 100 mg/dL	Creatine phosphokinase	123 U/L	< 171 U/L
VLDL cholesterol	18 mg/dL	0-40 mg/dL	Albumin	4.06 g/L	3.5-5.5 g/L
Urea	39 mg/dL	15-40 mg/dL	PCR	1.46 mg/L	0.0-8.0 mg/L
Creatinine	0.9 mg/dL	0.4-1.4 mg/dL	TPA	14 seconds	10-14 seconds
AST	27 U/L	5-38 U/L	APTT	55.7 seconds	27-38 seconds
ALT	12 U/L	10-40 U/L	INR	1.09	1.0-1.08

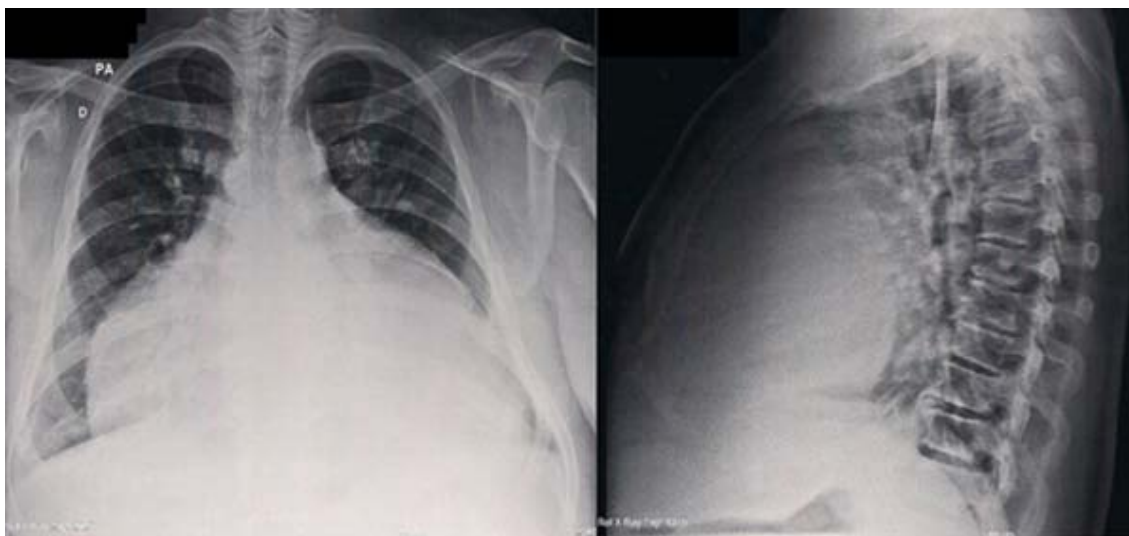


Fig. 1 Chest radiography demonstrating cardiac area increased.

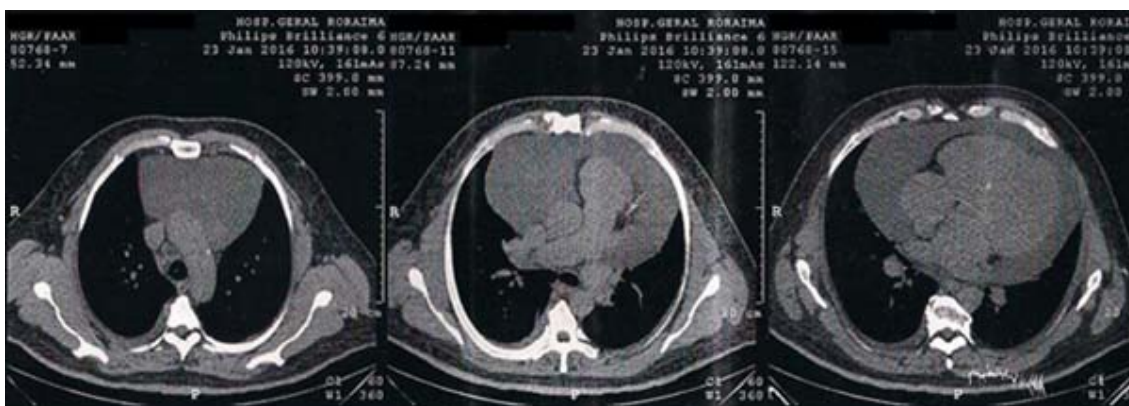


Fig. 2 Chest computed tomography showing massive pericardial effusion.

to culture tests, rapid molecular test and smear microscopy for tuberculosis, all tests cited above had a negative result. The removal of a fragment of the pericardial sac for pathological analysis found a fibrous thickening associated with a chronic inflammatory infiltrate and negative neoplastic cells research. The smear microscopy for tuberculosis of the pericardial sac fragment was also negative. The laboratorial analyses of the withdrawn pericardial liquid showed the following results: white blood cells $27 \times 10^3/\text{mm}^3$ (0-5); red blood cells $10 \times 10^3/\text{mm}^3$ (absent); polymorphonuclear cells 37%; mononuclear cells 63%; glucose 116 mg/dL (50-70); total proteins 6.7 g/dL (6.0-8.0); albumin 3.9; LDH 468 U/L (200-480); triglycerides 31 mg/dL.

A new echocardiogram was performed on 03/02/16,

it demonstrated ejection fraction of 43%, discrete pericardial effusion, global dilatation of the cardiac chambers, important eccentric hypertrophy and moderate systolic dysfunction of left ventricle, aortic escape, discrete mitral and tricuspid refluxes and aortic and pulmonary valves with normal morphodynamic aspects.

During the hospital internment and after the medical staff conducts, the patient evolved with clinical improvement, hemodynamically stable, with total remission of dyspnea. He was discharged on 03/04/16 and referred to the outpatient clinics of cardiology, endocrinology, vascular surgery and thoracic surgery, he was orientated to continue the use of levothyroxine to treat hypothyroidism.

In the outpatient follow-up a new chest radiography

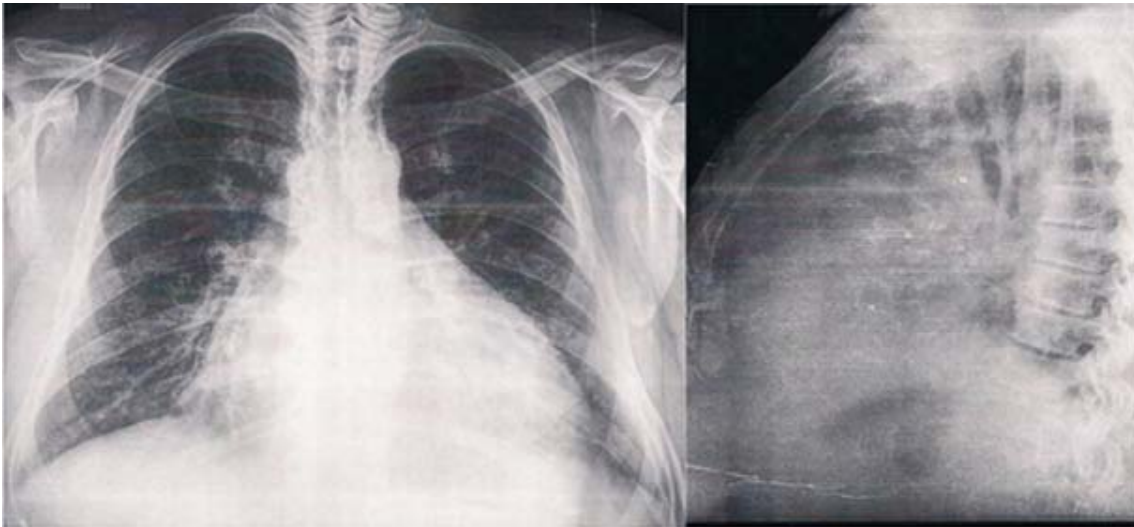


Fig. 3 Chest radiography demonstrating cardiac area decreased.

was requested (Fig. 3), in which was noticed a decrease of the cardiac area. The patient reported was asymptomatic.

However, after more than a year of treatment, unfortunately the patient was admitted to the HGR emergency with disorientation and tachyarrhythmia. He evolved with cardiorespiratory arrest, in this moment was initiated maneuvers of resuscitation and infusion of vasoactive drugs, the asystole rhythm remained, and the death of the patient was decreed on 11/26/17.

3. Discussion

Pericardial effusion is considered one of the most common complications caused by hypothyroidism, it can reach approximately 30-80% of patients [6, 7]. However, according to some authors, the explanation for this high prevalence is usually the association with more severe cases of the disease [8].

In the severe hypothyroidism is usual the increase of the cardiac area and the heart beats can present a low rate. This fact is often, in large part, due to the fluids rich in protein and glycosaminoglycans effusion to the pericardial sac, but the myocardium can be dilated as well [4].

Although some authors believe this effusion is caused by a combination of an albumin overflow and

decreased lymphatic flux [10].

The pericardial effusion is rarely extensive enough to lead to cardiac tamponade, because the fluid accumulation is usually slow and the pericardial sac is distensible [10]. Besides that, the effusion is probably the cause for the low amplitude of the electrocardiogram in the severe hypothyroidism [4]. The echocardiographic studies have revealed left ventricular dysfunction early in the disease. Such fact corroborates with the patient findings, who had already presented dilation, hypertrophy and moderate systolic dysfunction since the beginning of the condition. Some studies also described this finding in the subclinical hypothyroidism [11].

The term cardiac myxedema was used to establish the combination of cardiac enlargement and changes in hemodynamics, electrocardiography and enzymes. The treatment with thyroid hormone, in the absence of underlying cardiac disease, corrects the changes related to this myxedema, which restores normal heart size [4].

Hypothyroidism is often associated with elevated levels of total cholesterol and LDL cholesterol. Some patients can present high levels of triglycerides and C-reactive protein as well [12]. These changes regress after hormonal treatment. Patient's laboratorial tests showed, even with hypothyroidism, his levels of total cholesterol and LDL cholesterol was normal, just like

the levels of triglycerides and C-reactive protein. By analyse of the lipidogram, the unique notable alteration is the low level of HDL cholesterol, but the concentrations of this lipoprotein are not influenced by the thyroid functional situation [4].

It's important to note that, in this study case, the levels of TSH were high. However, free T4 levels were normal, within the reference range. Therefore, it is possible to affirm that the patient carries subclinical hypothyroidism. As already mentioned, the chances of hypothyroidism manifests as a large pericardial effusion are very low. The patient did not present typical signs and symptoms of the disease; the fact that free T4 was normal confirms that it was a subclinical hypothyroidism instead of a clinical one. This way, its possibility of manifesting as an effusion is even more unlikely.

4. Conclusions

In the view of the case above, it is possible to conclude that although the massive pericardial effusion is not the initial more common manifestation of hypothyroidism, in some cases it can arise before the clinical characteristics of the disease become evident. Therefore, hypothyroidism should always be considered in the differential diagnosis to avoid recidivism and serious complications, as cardiac tamponade and its repercussions.

Declarations

There was not any financial support to this work.

References

- [1] Dayan, C. M., and Daniels, G. H. 1996. "Chronic Autoimmune Thyroiditis." *New England Journal of Medicine* 335: 99-107.
- [2] Pearce, E. M., Farwell, A. P., and Braverman, L. E. 2003. "Thyroiditis." *New England Journal of Medicine* 348: 2646-55.
- [3] Neves, A. I. A., Neto, N. C. M., Maia, C. O., and Padilha, A. A. 2011. "Derrame Pericárdico como Forma de Apresentação do Hipotireoidismo Secundário à Radioablação com Iodo." *Revista Brasileira de Cardiologia* 24 (4): 258-61.
- [4] Kronenberg, H. M., Melmed, S., Polonsky, K. S., and Larsen, P. R. 2010. *Williams Tratado de Endocrinologia*. Translation of 11th Edition. Publisher Elsevier, 318-70.
- [5] Hollowell, J. G., Stehling, N. W., Flanders, D., et al. 2002. "Serum TSH, T4, and Thyroid Antibodies in the United States Population (1988 to 1994): National Health and Nutrition Examination Survey (NHANES III)." *Journal of Clinical Endocrinology & Metabolism* 87: 489-99.
- [6] Silva Jr, L. F. R. F., Provenzano, S. S. N., and Abreu, L. M. 2002. "As alterações cardiovasculares nas doenças tireoidianas." *SOCERJ* 15 (1): 21-33.
- [7] Okumura, A. C., and Uchida, M. 2009. "Tamponamento cardíaco como manifestação de hipotireoidismo." *Perspectivas Médicas* 20 (1): 34-7.
- [8] Kabadi, U. M., and Kumar, S. P. 1990. "Pericardial Effusion in Primary Hypothyroidism." *American Heart Journal* 120: 1393-5.
- [9] Shastri, R. M., and Shastri, C. C. 2007. "Primary hypothyroidism with pericardial tamponade." *Indian Journal of Pediatrics* 74 (6): 580-1.
- [10] Parving, H. H., Hansen, J. M., Nielson, S. L., Rossing, N., Munck, O., and Lassen, N. A. 1979. "Mechanisms of Edema Formation in Myxedema: Increased Protein Extravasation and Relatively Slow Lymphatic Drainage." *New England Journal of Medicine* 301: 460-5.
- [11] Biondi, B., Palmieri, E. A., Lombardi, G., et al. 2002. "Subclinical Hypothyroidism and Cardiac Function." *Thyroid* 12: 505-10.
- [12] Kvetny, J., Heldgaard, P. E., Bladbjerg, E. M., et al. 2004. "Subclinical Hypothyroidism Is Associated with a Low-Grade Inflammation, Increased Triglyceride Levels and Predicts Cardiovascular Disease in Males Below 50 Years." *Clinical Endocrinology (Oxf)* 61: 232-8.