

# Difficult Endotracheal Intubation—Scales and Causes

Dejan Stojanovic

*Health Center Bujanovac, The Department of Emergency Medicine, Bujanovac 17520, Serbia*

**Abstract:** The aim of the study is to assess the possibility of intubation in each patient, the lyche to be difficult intubation, to find all the causes of the difficult intubation, to find and apply appropriate scales for difficult intubation, to estimate the frequency of difficult intubation. Endotracheal intubation is the basic reanimation procedure performed both in hospital and out-of-hospital settings. It is carried out whenever chest movements and spontaneous respiration are compromised. Respiratory arrest may occur for a variety of reasons (such as cardiac arrest, coma of any origin, poisoning) or direct damage to the airways, e.g. in various traumas (damages to the face, oropharynx, larynx, trachea, chest). The basic endotracheal intubation kit contains: laryngoscope, endotracheal tubes, connectors (tube and Ambu bag connectors), complete Ambu kit (face mask and bag), 20 mL syringe for cuff inflating, suction apparatus, stylete, and Magill forceps. In order to assess the successfulness of endotracheal intubation, it is necessary first to identify patients who need to be intubated. With the aim of identifying such patients, numerous screening tests and scales have been created to predict difficult intubation. The best known and most commonly used are the Mallampati and Wilson classifications as well as the LEMON airway assessment method. Nevertheless, difficult intubation accounts for 1% of cases. It usually occurs when manipulation of the laryngoscope blade is not possible in obese patients and patients with short neck, in congenital restricted mouth opening, limited neck movement as well as limited temporomandibular joint mobility; in cases of edema, fibrosis and lesions of the tongue, pharynx and larynx; when there are anatomical variations and congenital malformations of the oral cavity, pharynx, larynx, head, neck and chest.

**Key words:** Endotracheal intubation, difficult intubation, screening tests, laryngoscope, airway.

## 1. Introduction

Airway management and lung ventilation are the first steps in primary management of critically ill patients, irrespective of etiology and kind of a life-threatening disorder. The best and the safest way to secure the airway is to perform tracheal intubation i.e. to introduce an endotracheal tube directly into the trachea, to secure and maintain the airway is the primary task as well as responsibility of a physician who gives first aid to a critically ill patient. Cessation of gas exchange just for a few minutes can lead to catastrophic consequences such as brain damage and death. According to the data of the WHO (world health organization), about 600 people die every year due to the consequences of difficult or impossible intubation. Endotracheal intubation maintains an open airway, enables aspiration in the tracheobronchial tree as well as the delivery of high

concentrations of oxygen; it serves as an alternative medication route for administration of certain drugs, whereas inflating the tube cuff can protect the airway from the aspiration of stomach contents or blood from the oropharynx. Endotracheal intubation is an optimal method which secures and maintains clear and open airway. It should be performed only by a skilled practitioner when all the necessary equipment is available.

Therefore, endotracheal intubation is the basic reanimation procedure performed both in hospital and out-of-hospital settings. It is carried out whenever chest movements and spontaneous respiration are compromised.

## 2. Airway Obstruction and Endotracheal Intubation

Airway obstruction occurs when the breathing passages contain some obstacle, making it hard or impossible to breathe. When airway obstruction is a

---

**Corresponding author:** Dejan Stojanovic, Ph.D. candidate, research fields: emergency medicine.

cause of failure or cessation of breathing, then it is usually sufficient to “free” the airway in order to establish spontaneous breathing. This is achieved by using various techniques and maneuvers (head tilt/chin lift and jaw thrust maneuvers, triple airway maneuver, lifting the mandible forward, removal of foreign material using fingers).

Airway obstruction may be partial or complete. The causes leading to the obstruction of the upper airway may be peripheral or induced by the CNS (central nervous system).

The causes of airway obstruction attributed to the CNS are numerous. Depression of CNS leads to decreased mandibular muscle tone, which further results in the airway obstruction caused by the tongue. Other causes of the CNS depression are as follows:

- All conditions leading to decreased cardiac output
- Cerebral ischemia
- CNS infection
- Head trauma
- Drug overdose
- Hypoxemia or hypercarbia
- Anesthesia
- Metabolic disorders
- Hyperthermia or hypothermia.

### 2.1 Peripheral Causes of Airway Obstruction

Any condition or illness which leads to the obstruction of the upper airways belongs to this category. There may be congenital syndromes associated with anomalies which lead to the airway obstruction (e.g. Down syndrome—people with Down syndrome may have large tongues), as well as a number of acquired conditions and diseases, such as:

- Tumors and various masses in the airways
- Trauma (especially acute laryngeal trauma)
- Drowning
- Burns
- Smoke and gas inhalation
- Anaphylaxis (followed by airway edema)
- Laryngospasm

- Bilateral vocal cord paralysis (recurrent laryngeal nerve injury, traumatic or iatrogenic).

The tongue is the most common cause of the upper airway obstruction, especially in unconscious patients. In such patients, the tongue base “closes” the hypopharynx for the following reasons:

- (1) In a comatose state, the cervical vertebrae tend to assume the semi-flexed position, reducing thus the distance between the tongue and pharynx.
- (2) Due to gravity, the epiglottis descends to the glottis.
- (3) Negative pressure ventilation pulls back (i.e. downward) the tongue base, closing thus the airway [1].

The basic endotracheal intubation kit contains:

- (1) Laryngoscope
- (2) Endotracheal tube
- (3) Connectors (tube and Ambu bag connectors)
- (4) Complete Ambu kit (face mask and bag)
- (5) 20 mL syringe for cuff inflating
- (6) Suction apparatus
- (7) Stylet (used for difficult intubation)
- (8) Magill forceps [2].

The laryngoscope enables the performance of laryngoscopy. i.e. a view of the glottis. There are various types and sizes of the laryngoscope, and the decision about the choice of the laryngoscope depends on the age and constitution of a patient as well as the assessment of intubation. The laryngoscope has a handle and a smooth, lighted tube, also called a blade. The handle contains a battery pack that supplies power to a light source inside the blade, which can be straight or curved. Even in 65% of the cases, the Macintosh (curved) blade is used for laryngoscopy in adult patients (Fig. 1). It may be of various sizes, from the largest (size 5) used on large adults, to the smallest (size 1) used on children. The largest and the smallest blades are used in 2% of cases only, whereas, most frequently, 70% of cases medium-sized blades (size 3) are used. Straight blades, most commonly the Miller–Phillips–Wisconsin, are used in infants in 20%

of cases, whereas the Foregger–Magill blades are used in 3% of cases. Namely, in infants, the epiglottis is relatively longer with respect to the oral cavity, and after placing the blade tip into the vallecula the epiglottis still keeps “hanging” and thus disturbs the visualization. For that reason, the blade tip is used to lift the epiglottis and enable visualization. In recent years, the McCoy blade with a flexible tip has been used, and it is very suitable for difficult intubation. During laryngoscopy using straight blades, the blade tip lifts the epiglottis; however, with a curved blade, the epiglottis lies below the blade tip.

Endotracheal tubes are plastic or rubber tubes which placed into the lumen of the trachea to maintain an open airway, and thus enable ventilation and oxygenation. The standard tube has the Ambu bag connectors and a labeled tube at which distal tip there is a cuff connected to the safety cuff. At the distal tip of the tube, below the cuff, there is an opening, called the “Murphy eye”, which secures ventilation in case of the occlusion of this part of the tube.

The cuff is a very important part of the tube. It

“seals” the trachea so as to prevent the leakage of the air during expiration, as well as the aspiration of regurgitated contents from the stomach and lungs (Fig. 1).

### 3. Technique of Performing Endotracheal Intubation

Orotracheal intubation is a medical procedure in which a tube is placed into the trachea through the mouth. It maintains an open airway and provides ventilation and oxygenation for a patient. During anesthesia, the delivery of anesthetic gases directly into the lungs of a patient goes smoothly. At the same time, the airway is protected from foreign material aspiration. In emergencies, if the vein route is not available (cardiopulmonary cerebral resuscitation—CPCR, great burns, etc.), an endotracheal tube can serve as a medication route for the administration of certain drugs. ETI (endotracheal intubation) remains the gold standard in maintaining the airway.

Indication for endotracheal intubation:



**Fig.1** Macintosh laryngoscope \*<sup>1</sup>.

<sup>1</sup> \* Enomoto Y, Br Y Anaesth, 2008.

- (1) Cardiopulmonary resuscitation
- (2) Respiratory failure
- (3) Protection of airway
- (4) Pulmonary toilet
- (5) Anesthesia with muscle relaxation
- (6) Mechanical lung ventilation
- (7) Comatose patients

In 1880, the Scottish surgeon William Macewen was the first to perform orotracheal intubation for an anesthetic. Standard technique of intubation means that the patient is in the supine position, on a flat surface, without head support, with the neck slightly flexed and the head extended.

A physician who performs endotracheal intubation is in a sitting or standing position, bent over the patient's head which is placed in the sniffing position. Literally translated, the verb "sniff" means to "smell or take by inhalation through the nose". The patient's head positioning during endotracheal intubation is very important for the visualization of the larynx and tube introduction. Neck extension allows the alignment of the oral, pharyngeal, and laryngeal axes with the laryngoscope blade. Neck extension occurs at the atlanto-occipital joint, and the occiput is aligned with the shoulders. If the patient wears a denture, it should be removed and the oral cavity should be cleaned off the foreign material. Oxygenation with pure oxygen using a mask ensues in duration of several minutes, especially in the intervals between failed intubations. Regardless of hand dominance, the laryngoscope is always held in the left hand, and the blade tip is introduced into the right hand side of the mouth. The tongue is swept to the left and the tip of the blade is advanced, which now allows the visualization of the oral cavity, then the uvula, base of the tongue, epiglottis and glottis. The laryngoscope blade should never be used as a lever, exerting a pressure on the incisors. Sliding along the tongue, the blade tip goes between the epiglottis and base of the tongue. Lifting the laryngoscope also lifts the epiglottis, allowing the visualization of the vocal

cords, i.e. the laryngeal inlet. As previously described, the straight blade is introduced into the right hand side of the mouth, and then moved centrally, pushing the tongue to the left. When the epiglottis is visualized, the blade tip is placed under the tip of the epiglottis, and by lifting the laryngoscope upwards, the larynx is exposed.

#### 4. Difficult Intubation

Difficult intubation has been defined in many ways, depending on the author. According to the Wilson criteria, difficult intubation is a failure to intubate the trachea at the first attempt without the help of assistant or use of supplementary technique, irrespective of the glottis visualization. According to the Cormack and Lehane criteria, difficult intubation is a failure to completely visualize the glottis during laryngoscopy, no matter whether tracheal intubation was successful at the first attempt or not (therefore, any "blind" intubation). Practically, following these criteria, difficult intubation and difficult laryngoscopy are equated. According to the criteria of the ASA (American Society of Anesthesiologists), difficult intubation is one during which the insertion of the endotracheal tube takes more than 10 min, or requires more than three attempts by an experienced anesthesiologist (regardless of the glottis exposure).

With the aim to prevent the serious consequences of difficult intubation, it is necessary to timely identify patients who need to be intubated. Therefore, numerous screening tests and scales have been created to predict difficult intubation. The ideal test for the assessment of the risk of difficult intubation should be simple, practical, highly sensitive and specific, with highly positive practical value, having clearly defined criteria, similarly determined by different observers.

##### 4.1 Mallampati Test

The Mallampati test is commonly used when the hypopharynx should be adequately visualized. Being in the seated position, the patient is asked to open the

mouth as wide as possible, and to stick out the tongue as far as possible. The examiner then inspects the oral cavity using a light source in order to assess the visibility of the hypopharynx. Being in the supine position, the patient is asked to open the mouth widely and protrude the tongue to its maximum. The examiner uses the laryngoscope light source in order to visualize the hypopharynx.

#### 4.2 Mallampati Classification

Class I: Visualisation of the soft palate, fauces, uvula, and pillars

Class II: Visualization of the soft palate, fauces and uvula

Class III: Visualization of the soft palate and base of uvula

Class IV: Only hard palate is visible [3].

#### 4.3 Wilson Score

The Wilson score is the most comprehensive screening score as it includes the largest number of variables for risk assessment. It involves detailed examinations of the (1) teeth and oral cavity, (2) mandible, (3) neck, and (4) other examinations.

(I) Examination of the teeth and oral cavity includes the following tests:

(1) The distance between the upper and the lower incisors (IIG—inter-incisor gap). If IIG is less than 3.5 cm, difficult intubation is more likely.

(2) Subluxation (S-lux)—maximal forward protrusion of the lower incisors beyond the upper incisors ( $S\text{-lux} > 0$ ;  $S\text{-lux} = 0$ ;  $S\text{-lux} < 0$ ). Difficult laryngoscopy and intubation are expected when protrusion is impossible or limited.

(3) The size and position of the teeth (especially incisors) are assessed subjectively (e.g. long, big, sharp, bad, loose, missing, etc.).

(II) Examination of the mandible involves the following tests:

(1) The length of the mandible from the temporomandibular joint to the lower incisors

(ML—mandibular length).

(2) Anterior mandibular depth is the distance between the lower incisors up to the top of the chin (AMD—anterior mandibular depth).

(3) Posterior mandibular length is the perpendicular distance from the mandibular plane to the alveolar margin of the mandible at position of the posterior border of the third molar (PMD—posterior mandibular depth).

(4) Mandibular recession is assessed subjectively (receding mandible is a predictor of difficult intubation).

(5) TMD (Thyromental distance) is measured from the thyroid notch to the tip of the jaw while the patient's neck is fully extended. It is also known as Patil's test. In a normal adult, the thyromental distance is greater than 6.5 cm;  $TMD < 6$  cm is associated with difficult intubation.

(III) Neck examination includes the following tests:

(1) Neck length is measured during neck extension, from the mastoid tip to the mid-portion of the ipsilateral clavicle (NL—neck length). Short neck is associated with difficult intubation. SMD (sternomental distance), the test frequently mentioned in the reference literature, is the distance between the sternum and the tip of the chin. Practically, this is equal to the neck length.

(2) NC (Neck circumference)—wide neck is a predictor of difficult intubation (especially if it is associated with shortness of neck).

(3) Head and neck movement was graded by Wilson as  $> 90^\circ$ ,  $80^\circ\text{--}90^\circ$  and  $< 80^\circ$ . Limited extension of neck (LEN) is a predictor of difficult intubation, especially if extension is  $< 90^\circ$  [1, 4].

(IV) Other examinations

(1) "Positive anamnesis" (information about prior difficult intubations).

(2) Body weight (BW), i.e. body mass index (BMI), as a more reliable parameter (compared to the absolute BW). If  $BW > 110$  kg, i.e.  $BMI > 30$  kg/m<sup>2</sup>, then difficult intubation is expected as obese patients are at

higher risk of difficult intubation.

#### 4.4 Novel and Rarely Used Tests

(1) MHD (mandibulo-hyoid distance) is defined as the vertical distance between the mandible and the hyoid bone (measured on a lateral x-ray of the neck with the head in neutral position). The greater the mandibulo-hyoid distance, the greater the possibility of difficult intubation. This test is rarely used as it requires an x-ray.

(2) HMD (hyomental distance) is a novel test which has proved to be a significant and reliable predictor of difficult intubation. It is measured in two neck positions: in the neutral- and head-extended positions. Both values are separate predictors, however, their ratio was proved to be a better predictor.

- Hyomental distance in head extension (HMD<sub>e</sub>) is the distance between the tip of hyoid bone to mental prominence in the position of maximum neck extension. HMD<sub>e</sub> < 5.3 cm is associated with difficult intubation.

- Hyomental distance in neutral neck position (HMD<sub>n</sub>) – HMD<sub>n</sub> ≤ 5.5 cm is linked to difficult intubation.

- HMDR (hyomental distance ratio) is defined as the ratio of hyomental distance at extreme of head extension to hyomental distance in neutral head position. HMDR is a predictor of decreased occipitoatlantoaxial extension capacity. HMDR ≤ 1.2 cm is a predictor of difficult intubation.

(3) ULBT (Upper lip bite test) is commonly used in combination with other tests (with hyomental distance, thyromental distance, and mandibular length) to predict difficult laryngeal visualization. This test is similar to the aforementioned S-lux test.

(4) Reclination is the test which measures the atlanto-occipital extension, and points to the position and mobility of the larynx. It is performed with the mouth wide open, the upper teeth are horizontal to the ground. The subsequent neck extension is classified into four grades. Grade 1 indicates normal values,

with the angle ranging from 30° to 35°. Grade 2 points to 1/3 of reduction, grade 3 indicates 2/3 of reduction, and grade 4 shows that extension is impossible. Grades 3 and 4 predict difficult intubation.

(5) Neck circumference/TMD ratio. This ratio is a better predictor of difficult intubation (better than several other, commonly used tests), especially in obese patients.

The introduction of a large number of tests for prediction of difficult intubation has increased their specificity, however, their sensitivity is still not high enough, so that none of the tests is reliable enough to predict or exclude the possibility of difficult intubation. Falsely positive tests do not pose any problem, as they in advance prepare the practitioner for difficult intubation. If intubation turned out to be simple, this cannot cause any harm to the patient. Conversely, falsely positive tests are actually problematic, and if they do not predict the possibility of difficult intubation, and such intubation unfortunately occurs, numerous complications and lethal outcome may ensue [1].

#### 4.5 Cormack-Lehane Classification

Cormack and Lehane defined the four-grade scoring system for prediction of difficult intubation based on inspection (Fig. 2):

(1) Most of the glottis is visible (with or without the epiglottis)

(2) Only the posterior portion of the glottis is visible

(3) Only the epiglottis but no portion of the glottis is visible

(4) Neither the glottis nor the epiglottis is visible.

Grades 3 and 4 are predictors of difficult intubation [5, 6].

#### 4.6 LEMON

The assessment of difficult airway using the LEMON method may be very useful in emergency situations, and it includes the following criteria:

L = Look externally. It is external inspection and estimation of characteristics that may be the cause of difficult laryngoscopy, intubation and ventilation (obesity, short neck, recession of the lower jaw).

E = Evaluate using the 3:3:2 rule. In order to align the oral, pharyngeal, and laryngeal axes and enable the simplest possible intubation, the following relationships should be considered:

- The inter-incisor distance with the mouth wide open should be 3 fingerbreadths (of the patient's fingers, and that is why number 3 is used). If the distance is smaller than 3 fingerbreadths, difficult intubation is very likely.
- The hyoid-mental distance should be 3 fingerbreadths, so all the values above or below this value are predictors of difficult intubation.
- The notch of the thyroid cartilage should be two fingerbreadths below the hyoid bone. The values above or below this value indicate difficult intubation.

M = Mallampati score. It is the aforementioned Mallampati score which should be used if necessary.

O = Obstruction (presence of any condition like

epiglottitis, peritonsillar abscess, trauma that could cause an obstructed airway, and therefore make laryngoscopy, intubation, and ventilation difficult).

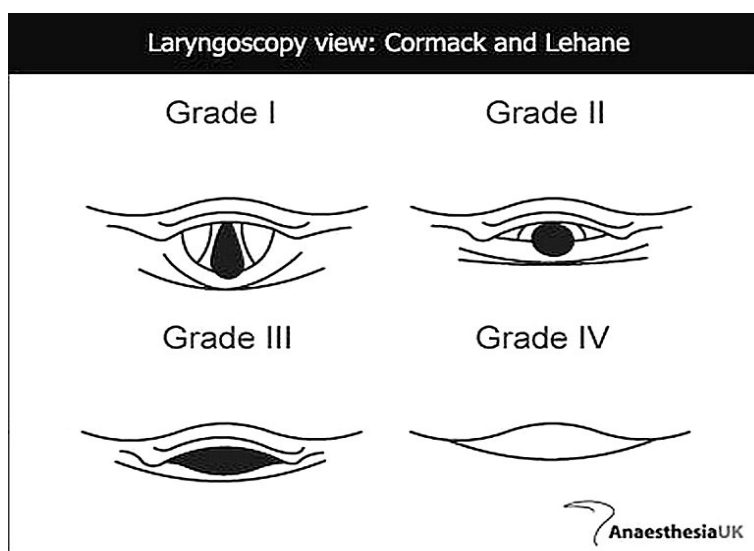
N = Neck mobility. This is a vital condition for successful intubation which can be easily assessed in the following way: ask the patient to bent their head forwards and place their chin on the chest, and then to tilt the head backwards as far as possible. Patients wearing a neck brace have limited neck mobility by definition, so in these cases, intubation is difficult [3].

#### 4.7 Macocha Score

Macocha sreening score was named after the place where scientists gathered to discuss about the predictors of difficult intubation. They concluded that the chief predictors of difficult intubation (with the incidence of 11,3%) should be:

A—Related to patient, including the following parameters:

- (1) Mallampati score III or IV
- (2) Obstructive apnea syndrome
- (3) Reduced mobility of cervical spine



**Fig. 2 Cormack-Lehane classification of difficult intubation \*\* <sup>2</sup>.**

Grade I—Visualisation of the entire glottic aperture.

Grade II—Visualisation of just arytenoid cartylages (cuneiform and corniculate) of posterior portion of glottic aperture.

Grade III—Visualisation of epiglottis only.

Grade IV—Visualisation of tongue or of tongue and soft palate only.

<sup>2</sup> \*\* Anaesthesia, UK.

B—Related to pathology:

(1) Severe hypoxemia

(2) Coma

C—Related to physician:

Anesthesiologist or some other specialist (who should be skillful and experienced).

All the seven points constitute the Macocha score [7].

In order to define DI (difficult intubation), IDS (intubation difficulty scales) are used. There is also the TAS (total airway score) for predicting DI defined by the IDS. Before intubation, the seven preoperative factors are assessed: Mallampati classification, thyromental distance, head and neck movements, BMI (body mass index), buck teeth, inter-incisor gap, and ULBT (upper lip bite test) (Table 1). Based on this assessment, TAS > 6 and ULBT class III are the

predictors of difficult intubation [8]. Some authors consider that Mallampati classification (class III and IV), thyromental distance < 6.5 cm, limited neck movement, inter-incisor gap < 2.5 cm, and body mass index > 26 are independent predictors of difficult intubation. The LEMON method for the airway assessment can also be used to predict difficult intubation in emergency centers. However, in critical situations, only 30% of the airways are assessed in this way [9]. Kim et al. defined the seven airway assessment factors by adding the Mallampati classification, thyromental distance, and the past history of difficult endotracheal intubation to the Wilson score. They concluded that the four following factors are of key importance: the Mallampati classification, thyromental distance, head and neck

**Table 1** Intubation difficulty scale \*\*\* <sup>3</sup>.

Airway Factors	Score		
	0	1	2
Mallampati Classification	class I	class II	class III-IV
Thyromental Distance (cm)	> 6.5	6-6.5	< 6
Head & neck movement (°)	> 90	90	< 90
BMI (kg/m <sup>2</sup> )	< 25	≥ 25	-
Buck teeth	No	Mild	Severe
Inter-incisor gap (cm)	> 5	4-5	< 4
ULBT	class I	class II	class III

**Table 2** Congenital syndromes associated with difficult intubation # <sup>4</sup>.

Syndrome	Causes of Difficult Intubation
Down, Turner	Large tongue, small mouth, small subglottic diameter
Goldenhar	Small mandible, spine deformity
Klippel-Feil	Nuchal rigidity (spinal fusion)
Treacher Collins	Mandibulofacial dysostosis
Pierre Robin	Mandibular anomalies, small mouth, large tongue

**Table 3** Acquired pathological conditions leading to difficult intubation ## <sup>5</sup>.

Organ/System	Pathological Conditions—Causes of Difficult Intubation
Mouth	Abscesses, papillomas, neoplasms, foreign body, soft tissue edema, traumas to the face and skull base, tetanus, glottic infections
Neck	Radiotherapy, trauma (edema, bleeding, emphysema), ankylosing spondylitis, burns, scars
Endocrine disorders	Thyromegaly, acromegaly, hypothyroidism (myxedema), diabetes mellitus, obesity
Other diseases	Upper respiratory tract infections, sarcoidosis, scleroderma, angiodema, croup

<sup>3</sup> \*\*\* Seo SH, Korean J Anaesthesiol, 2012.

<sup>4</sup> # Kalezic N, Initial treatment of emergency medical conditions, Belgrade, 2013.

<sup>5</sup> ## Kalezic N, Initial treatment of emergency medical conditions, Belgrade, 2013.



movements, and the past history of difficult endotracheal intubation [10]. Obesity and high BMI make intubation more difficult. Reduction of the BMI allows for increased inter-incisor gap, thyromental distance, and reduction in neck circumference, whereas the Mallampati classification remains the same [11]. Some authors state that obesity, obstructive sleep apnea and neck circumference are independent factors for the occurrence of difficult endotracheal intubation [12]. Difficult intubations mostly occurred in the IV Mallampati and IV Cormack group, which was expected. The most successful intubations were reported in the I Mallampati group (68.42 %) and the I Cormack group (63.16 %) [13]. The intubation success rate depends on the competence of the practitioner. Research has shown that physician-manned services achieved higher intubation success rates than non-physician manned services [14].

An alternative solution in cases of difficult intubation is the fiberoptic intubation, particularly in patients with spontaneous respiration. It is the camera-guided intubation, the gold standard and the technique of choice for skilled physicians, especially when direct laryngoscopy fails. Fiberoptic-assisted intubation enables ventilation and oxygenation in emergency situations. Portable fiberscopes can be used for emergency procedures, in a variety of settings [15]. In pediatric practice, special video laryngoscopes, such as GlideScope, C-MAC, Truview, McGrath, Pentax AWS, are used for airway visualization in cases of difficult intubation [16]. In traumatology, in cases of the cervical spine injuries when the patient's neck is immobilized with a cervical collar, the Airtraq laryngoscope has precedence over the McCoy laryngoscope, as the cervical collar does not have to be removed [17].

## 5. Causes of Difficult Intubation

Based on the aforesaid, difficult intubation occurs when (Table 2 and Table 3):

(1) Manipulation of the laryngoscope handle is not possible in patients with short neck and large amounts of fatty tissue on the anterior side of the chest (obese patients).

(2) There is congenital restricted mouth opening.

(3) Neck movement is reduced for various reasons (M. Behterev, neck scars).

(4) There is a limitation of movement of the temporomandibular joint due to trismus, scars around the lips, fibrosis, and local edema.

(5) There is surgical jaw fixation.

(6) Edema, lesion or fibrosis of the larynx, pharynx, tongue, etc. appear.

(7) There are anatomical variations, which are usually noticed during the prior inspection.

(8) There are congenital malformations, such as facial deformities, achondroplasia, Marfan syndrome, cystic hygroma, macroglossia, protruding or receding lower jaw, etc.

(9) There are burns or scars after serious burns to the face and neck.

(10) There is a risk of tooth damaging (bad, loose, fragile teeth, prosthetic treatment) [1, 2].

Therefore, the reasons for difficult intubation are numerous. They can be classified into two groups: congenital syndromes associated with various anomalies, and acquired conditions and diseases.

Intubation may be difficult, inappropriate or impossible not only in patients with objective reasons for difficult intubation. The reasons for difficult and inappropriate intubation in patients with normal anatomy are as follows: bad position of the patient's head, inadequate approach to the mouth, the situations when the tongue covers the laryngoscope blade (leaning against the upper teeth), haste, poor equipment, inexperience, fear [1].

Also, some very rare causes of difficult intubation have been reported:

- Epiglottic cysts. Even though they are rare, asymptomatic epiglottic cysts may be the cause of unanticipated difficult airway, which may be a

potentially life-threatening situation [18].

- Severe laryngeal and tracheal stenoses [19].
- Anterior cervical osteophytes may lead to distortion of the airway and subsequently cause difficult intubation. The osteophytes may be associated with the syndrome of diffuse idiopathic skeletal hyperostosis, when they most commonly appear at the C2-C3, C6-C7 and Th1 level, and result in anterior displacement of the pharynx and the trachea [20].
- Osteochondroplastic tracheo bronchopathy [21, 22].
- Tonsillar hyperplasia, especially the lingual one, which is rare. In such cases, a double-lumen endotracheal tube is used, as well as a flexible fiberoptic bronchoscope with a small probe [23].
- Decreased tongue mobility. It is estimated using the Mallampati score [24].
- Oral submucous fibrosis [25, 26].
- Osteoma of the thyroid cartilage [27].
- Acromegalic patients [28].
- Beckwith-Wiedemann syndrome (characterized by omphalocele, macroglossia, gigantism, hypoglycemia, and infantility). In this syndrome, macroglossia is considered to be the major risk factor for difficult intubation [29].
- Laryngeal edema [30].
- Subglottic stenosis, more common in children [31].
- Ectopic thyroid gland at the base of the tongue, where visualization of the glottis is impossible [32].
- Pharyngeal pouch [33].
- Calcified stylohyoid ligament [34].
- High voltage shocks [35].
- Pitt—Hopkins syndrome (characterized by intellectual disability, developmental delay, breathing problems, epilepsy, distinctive facial features) [36].
- Severely traumatized patients [37].

## 6. Conclusions

Significant in this study is that finding the cause of

the difficulty of intubation as well as assessing the scale of the difficulty of intubation does not guarantee the success of intubation.

No single indicator, combination of indicators, or even weighted scoring system of indicators can be relied on to guarantee success or predict inevitable failure for oral intubation. Application of a systematic method to identify the difficult airway and then analysis of the situation to identify the best approach, given the anticipated degree of difficulty and the skill, experience, will lead to the best decisions regarding how to manage the particular clinical situation. Assessing the airway preoperatively will allow you to choose the most appropriate and safest management technique, prepare back-up plans, and organize any extra equipment and personnel that may be required. In the future, it is necessary to search for new scales for assessing the difficulty of intubation, where their application in difficult intubation will shorten the time of intubation, find and apply new devices for difficult intubation, organize education and teams for difficult intubation, as well as their continuous training.

In spite of advances in medicine and search for better diagnostic strategies in diagnosing difficult intubation and improving the techniques of intubation, difficult intubation still remains a considerable problem both in prehospital treatment provided by emergency medical service and treatment received in a hospital setting. In recent years, many attempts have been made to overcome the problem of difficult endotracheal intubation. They have been focused on better diagnostics of difficult endotracheal intubation using various screening tests, introducing modified laryngoscopes and videolaryngoscopes for easier intubation, and finally on providing medical staff with comprehensive training indispensable for managing difficult endotracheal intubation.

## References

- [1] Kalezic, N., Palibrk, I., Videnovic, N., Sabljak, V., Janjevic, D., and Simic, D. Respiratory Tract and Artificial Ventilation of the Lungs: 21-79. In the

- editor's book: Kalezić, N. 2013. *Initial Treatment of Emergency Medical Conditions* (1st ed.). Belgrade. Medical Faculty in Belgrade.
- [2] Vucovic, D. Endotracheal Intubation: 55-62. In the editor's Vucovic, D. 2002. *Emergency Medicine* (1st ed.). Belgrade.
  - [3] Reed, M. J., Dunn, G. M. J., and Mc Keown, D. W. 2005. "Can An Airway Assessment Score Predict Difficulty at Intubation in the Emergency Department?" *Emerg Med J* 22: 99-102.
  - [4] Wilson, M. E., Spiegelhalter, D., Robertson, J. A., and Lesser, P. 1988. "Predicting Difficult Intubation." *BR J Anaesth* 61: 211-6.
  - [5] Enomoto, Y., Asai, T., Arai, T., Kamishima, K., and Okuda, Y. 2008. "Pentax—AWS, A New Videolaryngoscope, Is More Effective than the Macintosh Laryngoscope for Tracheal Intubation in Patients with Restricted Neck Movements: A Randomized Comparative Study." *Br J Anaesth*. 100 (4): 544-8.
  - [6] Krage, R., vain Rijn, C., van Groeningen, D., Loer, S. A., Swarte, L. A., and Schober, R. 2010. "Cormack—Lehane Classification Revisited." *Br J Anaesth*. 105 (2): 220-7.
  - [7] De Jong, A., Molinari, N., Terzi, N., Mongardon, N., Arnal, J. M., and Guitton, C. 2013. "Early Identification of Patients at Risk for Difficult Intubation in ICU: Development and Validation of the Macocha Score in Multicenter Cohort Study." *Am J Respir Crit Care Med*. 187 (8): 832-9.
  - [8] Seo, S. H., Lee, J. G., Yu, S. B., Kim, D. S., Ryu, S. J., and Kim, K. H. 2012. "Predictors of Difficult Intubation Defined by the Intubation Difficulty Scale (IDS): Predictive Value of 7 Airway Assessment Factors." *Korean J Anesthesiol* 63 (6): 491-7.
  - [9] Jigeshu, V. D., Parvez, U. K., and Sheila, N. M. "Tracheal Intubation in the ICU: Life Saving or Life Threatening." *Indian J Anaesth* 55 (5): 470-5.
  - [10] Kim, D. S., Ryn, S. J., Kim, K. H., Jang, T. H., and Kim, S. H. 1997. "Evaluation of Airway Assessment Factors for Predicting Difficult Intubation." *Korean J Anesthesiol* 32: 51-6.
  - [11] Lima Filho, J. A., Ganem, E. M., and de Cerqueira, B. G. 2011. "Reevaluation of the Airways of Obese Patients Undergone Bariatric Surgery after Reduction in Body Mass Index." *Rev Bras Anesthesiol*. 61 (1): 31-40.
  - [12] Neligan, P. J., Porter, S., Max, B., Malhotra, G., and Greenblatt, E. P. 2009. "Obstructive Sleep Apnea Is Not A Risk Factor for Difficult Intubation in Morbidly Obese Patients." *Anesth Analg*. 109 (4): 1182-6.
  - [13] Ita, C. E., Eshiet, A. I., and Akpan, S. G. 1994. "Recognition of the Difficult Airway in Normal Nigerian Adults (A Prospective Study)." *West Afr J Med*. 13 (2): 102-4.
  - [14] Lossius, H. M., Røislien, J., and Lockex, D. J. 2012. "Patient Safety in Pre-Hospital Emergency Tracheal intubation: A Comprehensive Meta-analysis of the Intubation Success Rate of EMS Providers." *Crit Care*. 16 (1): 24.
  - [15] Koerner, I. P., and Brambrink, A. M. 2005. "Fiberoptic Techniques." *Best Pract Res Clin Anaesthesiol* 19 (4): 611-21.
  - [16] Ramesh, S., Jayanthi, R., and Archana, S. R. 2012. "Paediatric Airway Management: What Is New?" *Indian J Anaesth*. 56 (5): 448-53.
  - [17] Durga, P., Kaur, J., Ahmed, S. Y., Kaniti, G., and Ramachandran, G. 2012. "Comparison of Tracheal Intubation Using the Airtraq® And McCoy Laryngoscope in the Presence of Rigid Cervical Collar Simulating Cervical Immobilisation for Traumatic Cervical Spine Injury." *Indian J Anaesth*. 56 (6): 529-34.
  - [18] Sonny, A., Nagaraj, G., and Ramachandran, R. 2011. "Asymptomatic Epiglottic Cyst: A Rare Cause of Unanticipated Difficult Intubation." *Middle East J Anesthesiol* 21 (1): 119-20.
  - [19] Wu, G., Li, Y. D., Han, X. W., Zhang, W., Han, X. P., and Ding, P. X. 2011. "Sheath-Assisted Tracheal Intubation: A Further Treatment Option for Patients with Acute Dyspnea of Asphyxia Caused by Severe Stenosis of the Larynx or Trachea." *Ann Thorac Surg*. 92 (2): 710-3.
  - [20] Vaibhavi, B., and Sucheta, G. 2010. "Diffuse Idiopathic Skeletal Hyperostosis of Cervical Spine—An Unusual Cause of Difficult Flexible Fiber Optic Intubation." *Saudi J Anaesth*. 4 (1): 17-9.
  - [21] Marchesani, F., Staccioli, D., Pela, R., Ranaldi, R., Cecarini, L., and Sanguinetti, C. M. 1993. "Tracheobronchopathia Osteochondroplastica." *Monaldi Arch Chest Dis*. 48 (3): 210-2.
  - [22] Smith, D. C., Pillai, R., and Gillbe, C. E. 1987. "Tracheopathia Osteochondroplastica: A Cause of Unexpected Difficulty in Tracheal Intubation." *Anaesthesia* 42 (5): 536-8.
  - [23] Orhan, M. E., Gözübüyük, A., Sızlan, A., and Dere, V. "Unexpected Difficult Intubation Due to Lingual Tonsillar Hyperplasia in A Thoracotomy Patient: Intubation with the Double—Lumen Tube Using Stylet and Fiberoptic Bronchoscopy." *J Clin Anesth*. 21 (6): 439-41.
  - [24] Rosenstock, C., and Kristensen, M. S. 2005. "Decreased Tongue Mobility—An Explanation for Difficult Endotracheal Intubation?" *Acta Anaesthesiol*

- Scand* 49 (1): 92-4.
- [25] Mahajan, R., Jaih, K., and Batra, Y. K. 2002. "Submucous Fibrosis Secondary to Chewing of Quids: Another Cause of Unanticipated Difficult Intubation." *Can J Anaesth*. 49 (3): 309-11.
- [26] Eipe, N. 2005. "The Chewing of Betel Quid and Oral Submucous Fibrosis and Anesthesia." *Anaesth Analg*. 100 (4): 1210-3.
- [27] Redman, A. G., Hide, I. G., and Zammit-Maempel, L. "Osteoma of the Thyroid Cartilage—an Unusual Cause of Difficult Intubation." *Br J Radiol*. 73 (872): 899-900.
- [28] Hakala, P., Randell, T., and Valli, H. 1998. "Laryngoscopy and Fiberoptic Intubation in Acromegalic Patients." *Br J Anaesth*. 80 (3): 345-7.
- [29] Kim, Y., Shibutani, T., Hirota, Y., Mahbub, S. F., and Matsuura, H. 1996. "Anesthetic considerations of two sisters with Beckwith—Wiedemann syndrome." *Anesth Prog*. 43 (1): 24-8.
- [30] Benumof, J. L. 1991. "Management of the Difficult Adult Airway with Special Emphasis on Awake Tracheal Intubation." *Anesthesiology* 75 (6): 1087-110.
- [31] Nicklaus, P. J., Crysdale, W. S., Conley, S., White, A. K., Sendi, K., and Forte, V. 1990. "Evaluation of Neonatal Subglottic Stenosis: a 3 Years Prospective Study." *Laryngoscope* 100 (11): 1185-90.
- [32] Lammer, H., Mitterschiffthaler, G., and Fischer, F. "The Lingual Thyroid, an Unexpected and Rare Intubation Difficulty." *Anaesthesist* 38 (4): 206-7.
- [33] Bray, R. J. 1977. "Pharyngeal Pouch as a Cause of Difficult Intubation." *Anaesthesia* 32 (4): 333-5.
- [34] Walls, R. D., Timmis, D. P., and Finucane, B. T. 1990. "Difficult Intubation Associated with Calcified Stylohyoid Ligament." *Anaesth Intensive Care* 18 (1): 110-2.
- [35] Van Zudert, A., Stessel, B., De Ruiter, F., Giebelen, D., and Weber, E. 2007. "Video—Assisted Laryngoscopy: A Useful Adjunct in Endotracheal Intubation." *Acta Anaesthesiol Belg*. 58 (2): 129-31.
- [36] Navaratnarajah, J. 2013. "Previously Unreported Difficult Intubation in A Child With Pitt—Hopkins Syndrome." *Paediatr Anaesth* 23 (12): 1226-7.
- [37] Lecky, F., Bryden, D., Little, R., Tong, N., and Moulton, C. 2008. "Emergency Intubation for Acutely Ill Injured Patients." *Cochrane Database of Systematic Reviews* (2): cd001429.